

Health impact of electric discharge weapons, a review of case studies

Marie Brasholt¹, Maha Aon^{1,2}, Lisa Michaelsen¹ and Jens Modvig¹

1 DIGNITY, Danish Institute against Torture.

2 American University of Beirut (AUB)

Key points of interest

- The review assembles findings from case studies about the health effects of electric discharge weapons (EDWs) which are increasingly used by law enforcement agencies.
- The case studies document a broad range of adverse health outcomes including death after EDW exposure.
- When assessing patients exposed to EDWs, including in torture and ill-treatment cases, it is important to be aware of the different types of potential injury.

Abstract

Introduction: Electrical discharge weapons (EDWs) are increasingly used by law enforcement around the globe as a less lethal option to firearms. Concerns have been raised about their use, inter alia from the UN Committee Against Torture (UNCAT). The purpose of this manuscript is to provide an overview of case studies to assess the health consequences of EDW exposure. *Methods:* Medline and Pubmed were searched for case studies on EDWs without restriction on language or date. Screening was first at abstract level and then at full article level. Articles were excluded if they were not case studies, concerned children under 15 years old or were off topic. A PRISMA flow diagram was created. *Results:* A total of 71 studies were included, and they demonstrate a wide range of health consequences from minor injuries to lethal conditions. The injuries can be classified as direct and indirect, i.e., related to the use itself (e.g., penetration by darts) and related to falls and burns following neuromuscular incapacitation and ignition of flammable fluids. Cardiac incidents – some being fatal – as well as eye injury were the health consequences found most reported. Description of pain and mental suffering related to EDW exposure was lacking in the reviewed case studies. *Discussion:* Evidence in the reviewed case reports demonstrates that EDWs have in fact led to physical and most likely mental suffering and even death, notwithstanding the epidemiological limitations of case reports in establishing causality at population level. When assessing patients and when documenting cases where persons may have been exposed to EDWs, including torture and ill-treatment cases, it is important to be aware of the different types of health consequences.

Keywords: Electric discharge weapon (EDW), Conducted energy weapon (CEW), Conducted energy device (CED), taser, adverse health effects.

Introduction

Electric discharge weapons (EDWs) are hand-held devices that by means of electrical current induce pain or disrupt voluntary control of muscles, causing neuromuscular incapacitation.

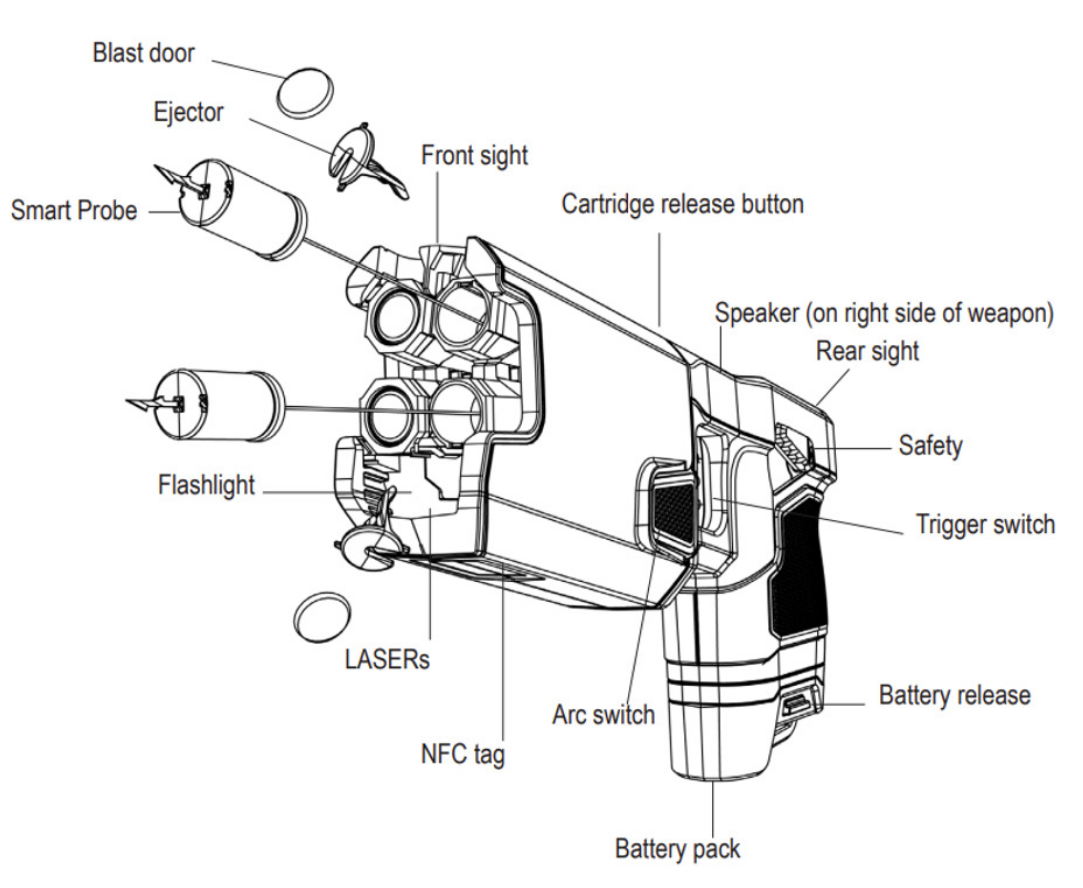
An EDW is either a direct contact weapon such as a stun gun or a projectile weapon referred to as a conducted electric/electrical/energy device/weapon (CED) or (CEW) which can be shot at the subject, such as the Taser.

A stun gun generates high voltage low amperage current and can be activated when the weapon is pressed directly against a person so that its electrodes come in direct contact with the skin of the person. The weapon induces severe pain, expected to ensure compliance. Thick clothes may, however, reduce the current and thereby the effect.

CEDs use compressed nitrogen to fire two probes connected to the device through wires from a distance of up to

13.7 meters (Taser 10) (Axon Law Enforcement, 2024). The probes may be referred to as darts and consist of a metal barb that penetrates clothes and skin down to around 6 mm depth, delivering a series of ultrashort electrical pulses of a duration of around 0.1 second. This use of the weapon (“probe mode”) affects nerve fibers and to some degree muscle tissue directly, leading to substantial pain and, if the probes are sufficiently separated, involuntary muscle contractions and loss of regional muscle control (neuromuscular incapacitation), causing the person to fall to the ground (Kunz et al., 2024). In addition, heat induced injuries may develop in skin and other soft tissue with high resistance, as seen in accidental electrical injuries (Mansueto et al., 2021). Most CEDs can also be used as a stun gun (“drive-stun” mode) and be pressed directly towards the target to deliver painful electrical shock.

Figure 1. Diagram of Taser 7



Source: Axon Enterprise, Inc. (2024). TASER 7 and TASER 7 CQ Energy Weapons User Manual.

Similar to stun guns, other devices relying on pain compliance through electric shock include electric shock batons and stun cuffs as well as electric stun vests, electric riot shields and stun sleeves which have been banned in the European Union since 2006 (European Council, 2011).

Updated data on global usage of EDWs are not readily available, but it was estimated in 2011 that EDWs were used by over 15,000 law enforcement and military agencies (Holder et al., 2011). EDWs are promoted as less-lethal weapons in comparison to deadly force (firearms). While there exists no official universal model for the use-of-force continuum, it is inherently understood that legitimate force is that which complies with the law, is necessary because all less-violent methods have been exhausted and allows an officer to manage the risk with proportionate force. Many law enforcement agencies have guidance on the degree of force to be used based on the situation. This may start with mere officer presence moving up to verbal communication, then mild physical force potentially moving up to stronger physical force and then the use of tools such as batons, pepper spray or EDWs. The final stage in the use of force continuum is deadly force such as use of firearm (NIJ, 2009). The United Kingdom police force for example, place the Taser M26 directly before firearms in their hierarchy of use-of-force (Jenkinson et al., 2006).

Taser safety and health information issued by its producer lists potential adverse effects including bone fractures, injuries due to falls or uncontrolled movement, and increased risk of seizures. The information note warns against usage on “pregnant, infirm, elderly, low body-mass index persons or small child” and states that injuries are more likely among “people with pre-existing injuries, orthopedic hardware, conditions or special susceptibilities, including pregnancy, low bone density, spinal injury, or previous muscle, disc, ligament, joint, bone or tendon damage or surgery.” (Axon Enterprise, Inc., 2018).

The United Nations Committee against Torture (UNCAT) is concerned by the risk of excessive use of force via CEDs and recommends States to ensure that their use is limited to situations where there is an immediate threat to life or risk of serious injury, to prohibit their use against minors, pregnant women, and in health care and custodial settings, to ensure that their use is in compliance with the prohibition of torture and the principles of necessity and proportionality, and to ensure proper training in their use and safeguarding against their misuse (UNCAT, 2018). The Committee expressed “deep concern” in its review of Portugal in 2008 regarding the purchase of Taser X26 by the State concluding that the impact of the weapon “would appear to violate articles 1 and 16 of the Convention [against torture]” relating to the definition of torture and to

state obligation to prevent torture (UNCAT, 2008). Similarly, the European Committee for the Prevention of Torture and Inhuman or Degrading Treatment or Punishment (CPT) investigated and documented allegations of ill-treatment or torture related to the use of EDWs by law enforcement in countries including Bulgaria and Russia (Council Of Europe, 2013, 2015).

A 2021 systematic review on the health risks of Tasers found that the risk of adverse outcomes due to use is low (Baliatsas et al., 2021). However, the review also identified methodological and quality issues with most studies. Studies were all experimental, largely recruiting a small sample of healthy individuals who are unlikely to represent the population exposed to Tasers. The review further found that many studies received funding from the Taser manufacturer (Baliatsas et al., 2021). The finding that there is a need for higher quality research is echoed in other reviews (Semple et al., 2021; Sheppard & Welsh, 2022).

Nevertheless, studies report that injuries occur in 20% - 41% of cases involving a range of EDW use (Gardner et al., 2012; Terrill & Paoline, 2012). For example, one study of police departments in California, found a 6.4-fold increase in the rate of in-custody deaths not involving firearms force compared to the average mortality rate in the five years prior to Taser deployment (Lee et al., 2009). The rate decreased to pre-deployment levels after 2-5 years. Studies have documented a broad range of physical injuries from EDW use in the law enforcement context (Lokdam et al., 2018).

The purpose of the current review is to examine case studies to assess the health consequences of EDW use. This will contribute to knowledge on EDWs since recent systematic reviews have excluded case studies, and there currently does not exist an overview of the types of adverse health consequences that have occurred upon application of an EDW.

Methods

This is a review of case studies on the health impact of EDWs. The search was conducted on two search engines Medline through the Ovid interface and Pubmed. The MeSH term *Conducted Energy Weapon Injuries* was applied along with *stun gun* and *taser* as keywords. The search was limited to a focus on humans and a case study design, but no other restrictions were applied such as language or publication year. See search strategies in the supplementary material. The search was complemented with handsearching. Exclusion criteria were wrong study design (not case study), subject below 15 years of age or study not addressing the health consequences of EDW use (off topic). Article selection took place in two stages. Two authors (physician and epidemiologist) screened titles and abstracts in parallel. Full article texts were obtained and screened by one author (physician)

who also conducted the handsearching for additional literature. All articles were uploaded in Zotero reference manager software (Takats et al., 2023). All articles except three were in English. Two in French could be read by the authors and one in Russian was machine translated into English by DeepL (DeepL SE, n.d.).

A data extraction form was created in Excel and populated by one author (physician) with data on the year of publication, age and gender of the victim(s), the type of weapon used, the affected organ and the health outcome. See the populated data extraction form in the supplementary material. The data extraction form was then analyzed by grouping the case studies according to trauma mechanism, subdividing them into direct and indirect injuries and different relevant mechanisms under each of these headings.

Results

Our search yielded 121 reports from two search engines of which 54 were duplicates, six were excluded for being off topic, two for studying children, and one was the wrong study design. In addition to the resulting 58 records, 13 studies were identified through handsearching. A total of 71 studies were included in this review. See PRISMA flow diagram in the supplementary material as well as a bibliography of reviewed articles.

The 71 articles were published between 1987 and 2023. Only three were published before 2000, one in 1987, one in 1992 and one in 1997, none in the years 1998-2002, and the rest from 2003 onwards.

Weapons used were most often described as Tasers. Five used the more general terms CED/CEW and two used the term stun gun. However, it is unclear whether the word “taser” was used by some authors as a general term for an electrical discharge weapon. Only thirteen authors provided the full details of the weapon model. In many cases, it was clear if a CED/CEW had been used from a distance because the darts were subsequently located, but if the presence of darts was not described, it was often unclear whether a device could have been used in “stun-drive” mode (direct contact). In addition, many case studies did not specify the number of times a weapon was discharged on an individual.

Not all studies provided information about the gender of the person on whom the device was used, but most did, and they revealed a far larger number of men than women with only 7 women as opposed to 91 men in the 71 case studies. In 12 cases, the gender was not reported. Ages ranged from 15 to 61 years.

In addition to written case descriptions, many studies included pictures illustrating the physical damage described as well as other examination results such as X-rays and electrocardiograms (ECGs).

Overall, the reviewed articles covered two different types of injuries related to EDW incidents: Injuries directly caused by the EDW and injuries related to the circumstances around the use of the EDW.

Direct injuries

Direct injuries resulting from EDW exposure can be subdivided into four categories:

1. Injuries caused barb and/or dart penetration.
2. Injuries directly related to the electrical discharge.
3. Injuries related to electrically induced muscular contraction.
4. Injuries where it has not been possible to establish the exact mechanism.

1. Penetrations by barbs and darts

Injuries by CED barbs and darts to many different body parts have been reported:

Skull

Eight single-case studies report damage to the skull by penetrating darts (Chandler et al., 2013; Cheek et al., 2013; Crawley et al., 2023; Delavar & Thompson, 2021; Le Blanc-Louvry et al., 2012; Lewis & Lewis, 2016; Mangus et al., 2008; Rehman et al., 2007). In three of the cases, the dart was lodged in the bone and could be successfully removed, in two it had penetrated the frontal sinus, in one it had penetrated through the bone but not reached the brain tissue, and in two cases the dart had penetrated through the bone into the underlying brain tissue. In two of the three cases where the dart penetrated the bone to the brain, no health consequences were reported, but in the third one, where a small bleeding (hemorrhage) had formed in the frontal part of the brain around the tip of the dart, and after removal of the dart, the patient reported persistent throbbing headaches during physical efforts and certain movements of the head (Le Blanc-Louvry et al., 2012).

Eyes and surroundings

Injury to the eyes and surrounding area is among the most frequently reported injuries caused by penetration by darts and barbs. Out of 15 such cases reported, at least three resulted in removal of the eye or parts of the eye (enucleation or evisceration) due to irreversible damage with loss of vision, and in others there was a substantial reduction of vision (Chen et al., 2006; de Runz et al., 2014; Gapsis et al., 2017; Han et al., 2009; Jey et al., 2016; Li & Hamill, 2013; Moysidis et al., 2019; Ng & Chehade, 2005; Rafailov et al., 2017; Sharabura et al., 2021; Teymorian et al., 2010). In one lucky incident, the eye hit was the one

where a person already had an implant, whereas the only seeing eye was spared (Moysidis et al., 2019).

Face

Only one study reported penetrating midfacial injury (Campbell & Clark, 2019). In this case, the barb became embedded in the area of the cheek below the eye (the sub tarsal region of the cheek), and surgical removal under general anesthetic was uncomplicated. Exploration of the wound exhibited no damage to adjacent structures.

Throat (pharynx), trachea and chest

One study reported on penetration of the pharynx (throat) that led to emphysema (air trapped in the tissues) on the upper part of the body. Surgery was required to investigate the extent and exact location of the injury (Al-Jarabah et al., 2008). Another study reported on possible penetration of the trachea leading to pulmonary interstitial emphysema and a pneumomediastinum (air in the mediastinum) (Maher et al., 2015). As an alternative explanation, the authors suggest that the mechanism could be a tracheal tear after a valsalva manoeuvre (forced expiration against a closed glottis). Finally, in one case a dart penetrated the pectoral (upper chest) muscle causing a pneumothorax (collapsed lung) (Hinchey & Subramaniam, 2009). One study documented a dart lodged in the clavicle (collar bone) (Willoughby et al., 2022).

Fingers

Five studies describe penetrating injury to fingers (Abdelaty et al., n.d.; Becour, 2013; De Courcey & Jones, 2021; Dearing & Lewis, 2005; Dunet et al., 2015). In three of these, penetration resulted in a fracture, and in two, a tendon was lacerated.

Testis

One study described penetration of a testicle leading to a small testicular hematoma (Theisen et al., 2016).

Gastro-intestinal tract

The earliest case identified in this review about the potentially harmful effects of a taser dart was published in 1987 and involved a psychiatric patient who following an incident with a Taser swallowed a dart that was lodged in his clothes (Koscove, 1987). After careful observation in hospital, the patient eventually passed the dart without any complications.

2. Electrically induced injuries

A range of injuries directly related to the electrical discharge from an EDW has been recorded similar to electrical injuries observed in other circumstances. These include:

Burns

Four articles describe burns following the use of EDWs (Abada et al., 2014; Anders et al., 2003; Burdett-Smith, 1997; Burmatov et al., 2011). The burns ranged in severity from superficial dot-like lesions to a severe extended burn on the scalp requiring plastic surgery. Interestingly, three of the four cases described were not related to law enforcement but to assaults.

Electrically induced cataract

One case of electrically induced cataract has been reported (Seth et al., 2007). In this case, the patient presented six days after having been exposed to EDW discharge in the face. A burn was found on the eyelid together with the cataract.

Brain injury

One case of tonic-clonic seizures following a Taser shot to the head was reported in a police officer in his thirties who was accidentally hit. The officer had no known history of epilepsy and did not experience any subsequent epileptic fits (Bui et al., 2009). In another case, an otherwise physically healthy 32-year old man presented to the emergency department following EDW discharge during an altercation with the police. Upon arrival, he had persistent change in mental status with speech difficulty as well as generalized right-sided weakness, and he had abrasions on the forehead from the EDW barb. It was found that the patient had developed cerebral infarction (an acute stroke). The authors conclude that electrical neurovascular injury with spasms and vasospasm and endothelial injury (injury of the blood vessels) was the most likely mechanism (Bell et al., 2013).

Cardiac arrhythmias

There is a complicated relationship between EDWs and the heart. The outcome of certain irregular heart rhythms is potentially fatal, so it may come as no surprise that this is the area where most single cases have been reported. Some of these have been directly attributed to the electricity caused by the EDW, among them one case of atrial fibrillation (irregular heart rhythm) that converted to a normal sinus rhythm immediately following an EDW incident (Richards et al., 2008). Another case involved a 16-year old who developed atrial fibrillation (Multerer et al., 2009). Interestingly, both cases involved a CED in drive mode, at least one of them being applied to the chest. In addition, no less than 11 cases of life-threatening irregular heart rhythms including ventricular tachycardia, ventricular fibrillation and asystole (lack of electrical impulses in the heart) have been reported (England et al., 2015; Kim & Franklin, 2005; Naunheim et al., 2010; Schwarz et al., 2009; Zipes, 2013). All cases involved discharge to the chest either directly or through darts. At least sev-

en of these cases had a fatal outcome. In all of these, loss of consciousness was seen in direct relation to the EDW incident(s). Cardiac rhythm was recorded in most cases five to ten minutes after loss of consciousness though in one case it only occurred thirty minutes later. In one case, asystole was recorded, while in the other cases ventricular tachycardia/ventricular fibrillation was observed. One person survived with memory impairment and two spent more than three weeks in hospital following the incident, one because of a complicating pneumonia in the aftermath of the incident and one for rehabilitation purposes. It is also worth mentioning that six of the reported cases occurred in very young men, one who was described as adolescent and five as 16-17 years old. Three of these did not survive.

Pacemakers may also be impacted by the electricity. In four cases involving one man in his twenties and three in their fifties who had pacemakers that recorded their heart rhythm, the recording showed myocardial capture/ventricular "fibrillation" during tasing (Cao et al., 2007; Haegeli et al., 2006; Paninski et al., 2013; Pope et al., 2023). In all cases, the recorded heart rhythm returned to normal spontaneously, and there were no clinical implications of the incidents. Nevertheless, some of the authors have speculated that such incidents could activate an implantable cardioverter defibrillator.

Nerve damage

One case reported on a woman assaulted directly on the neck with a stun gun (Bonnar et al., 2019). She developed an acute brachial plexus lesion (severe lesion of the nerves to the shoulder and arm) resulting in palsy and multimodal sensory loss in one arm (weakened arm muscles and loss of sensation in the arm), speculated to be the result of multiple stimulation and direct application to Erb's point. At two-years follow-up, weakness was still present in the deltoid (shoulder) muscle together with pain and reduced sensation in the forearm.

Delirium

One case story reports on a 37-years old man with no prior psychiatric history who developed agitation and delirium on EDW exposure leading him to spend three days in intensive care (Feehey et al., 2010). The authors conclude that the case raises the possibility that EDWs may cause or contribute to excited delirium because similar cases have been observed in persons who have otherwise been exposed to high levels of electric current.

Spontaneous abortion

One author reported on a spontaneous abortion of an 8-10 weeks pregnancy that started with spotting on the day follow-

ing the EDW event where darts hit one thigh and the abdomen above the uterus (Mehl, 1992).

3. Injuries due to muscular contractions

The EDW induces muscular contraction that may be so strong that it gives rise to damage to muscles, tendons and even bones.

Fractures

Three cases of compression fractures in the spine were reported, two of these having two or more simultaneous fractures (Sloane et al., 2008; Tyagi et al., 2017; Winslow et al., 2007). Interestingly, all cases were related to training of law enforcement officers. In addition, one case involving a fracture of the scapula (shoulder bone), also related to training was reported (Coad & Maw, 2014).

Tendon ruptures

One case of bilateral patellar (knee) tendon rupture has been attributed to EDW-induced muscle contraction (Hudak et al., 2011). Similarly, a case of rupture of the iliopsoas (hip) muscle and the gluteus minimus (smaller gluteal) tendons was reported (Giacconi et al., 2011). The latter case required surgical intervention.

Rhabdomyolysis

There are four cases reported in which rhabdomyolysis (a serious medical condition that can cause kidney failure) due to extensive muscle damage followed the use of an EDW (Gleason & Ahmad, 2015; Gross et al., 2013; Sanford et al., 2011). In one of the cases, the outcome was death due to permanent kidney failure (Gross et al., 2013). In two other cases, it was speculated that the involved young men had been in a physical fight which might also have caused muscle damage (Sanford et al., 2011).

4. Unknown mechanisms

In some instances, the exact pathogenetic mechanism has not been established. This includes three cases of acute myocardial infarction (heart attack) in healthy young men aged 20, 33 and 37 (Baldwin et al., 2010; Belen et al., 2015; Ben Ahmed et al., 2013). The pathogenesis of these myocardial infarctions is unknown, and they occurred at different times following the incident (immediately and after ninety minutes and four hours respectively), but Baldwin et al. speculate that it could be due to a spasm in the coronary artery (that supplies the heart muscle with blood) (Baldwin et al., 2010). Other cases are sporadic and include a person who suffered retinal detachment caused by bleeding speculated to have potentially resulted from thermal damage due to the electricity (Sayegh et al., 2011); a wom-

an with pre-existing conditions (systemic lupus erythematosus, kidney affection and potential hypertension) who suffered lupus coagulopathy (blood clotting complication) (Bryant et al., 2014); and a young male who developed hypertension and kidney affection leading to hospitalization after a Taser exposure. In this case, the authors conclude that it is unclear whether the EDW contributed to the kidney affection otherwise attributed to synthetic cannabinoids (Cooks et al., 2016).

Indirect injuries

The indirect injuries in relation to EDWs can be divided into three categories:

1. Falls
2. Burns
3. Aspiration

1. Falls

Falls may in fact be among the most frequently occurring negative consequences of the use of EDWs. In one mono-center study over five and a half years, 46 persons were seen who had been involved in EDW incidents (Becour, 2013). Of these, 18 had injuries stemming from falls during the incidents. These included cutaneous and subcutaneous hematomas and abrasions, as well as a fractured humerus (head of the bone of the upper arm) due to a fall on the shoulder, a scaphoid (wrist) bone fracture following a fall on the palm of the hand, and a digital (finger) fracture. In another study, 16 cases of fatal traumatic brain injury following falls during the incidents were identified (Kroll et al., 2016). In a third study, falls resulted in hematomas (serious bruises) to the skin, a nasal fracture, a fracture of the bone surrounding the eye and a skull fracture resulting in intracranial (brain) bleedings (Mangus et al., 2008). Finally, a 42-year-old man who threatened to stab himself with a knife, was subject-

Figure 2. Matrix of key findings

Body part	Documented damage	References
Skull and brain	<i>Penetration:</i> Darts lodged in bone, sinus and brain tissue.	Chandler et al., 2013; Cheek et al., 2013; Crawley et al., 2023; Delavar & Thompson, 2021; Le Blanc-Louvry et al., 2012; Lewis & Lewis, 2016; Mangus et al., 2008; Rehman et al., 2007.
	<i>Electrically induced damage:</i> Tonic-clonic seizure and acute stroke.	Bui et al., 2009; Bell et al., 2013.
	<i>Indirect injuries:</i> Traumatic brain injuries following falls, some fatal.	Kroll et al., 2016; Mangus et al., 2008.
Eyes	<i>Penetration:</i> Darts lodged in eye and surroundings, some with loss of vision.	Chen et al., 2006; de Runz et al., 2014; Gapsis et al., 2017; Han et al., 2009; Jey et al., 2016; Li & Hamill, 2013; Moysidis et al., 2019; Ng & Chehade, 2005; Rafailov et al., 2017; Sharabura et al., 2021; Teymoorian et al., 2010.
	<i>Electrically induced damage:</i> Cataract.	Seth et al., 2007.
	<i>Unknown mechanism:</i> Retinal detachment.	Sayegh et al., 2011.
Face	<i>Penetration:</i> Dart lodged in facial tissue.	Campbell & Clark, 2019.
	<i>Indirect damage following falls:</i> Fractures.	Mangus et al., 2008.
Throat, trachea and chest	<i>Penetration:</i> Emphysema, pneumomediastinum and pneumothorax.	Al-Jarabah et al., 2008; Maher et al., 2015; Hinchey & Subramaniam, 2009.
	<i>Indirect damage:</i> Aspiration causing fatal pneumonia.	Plenzig et al., 2021.

Body part	Documented damage	References
Heart	<i>Electrically induced damage:</i> Arrhythmias, some fatal.	Multerer et al., 2009; England et al., 2015; Kim & Franklin, 2005; Naunheim et al., 2010; Schwarz et al., 2009; Zipes, 2013.
	<i>Unknown mechanism:</i> Acute myocardial infarction.	Baldwin et al., 2010; Belen et al., 2015; Ben Ahmed et al., 2013.
Genitals	<i>Penetration:</i> Testis hematoma.	Theisen et al., 2016.
	<i>Electrically induced damage:</i> Spontaneous abortion.	Mehl, 1992.
Limbs and spine	<i>Penetration:</i> Fractures (of fingers) and laceration of tendons.	Abdelaty et al., n.d.; Becour, 2013b; De Courcey & Jones, 2021; Dearing & Lewis, 2005; Dunet et al., 2015
	<i>Damage due to muscular contractions:</i> Compression fractures, tendon ruptures, rhabdomyolysis.	Sloane et al., 2008; Tyagi et al., 2017; Winslow et al., 2007; Coad & Maw, 2014; Hudak et al., 2011; Giaconi et al., 2011; Gleason & Ahmad, 2015; Gross et al., 2013; Sanford et al., 2011.
	<i>Indirect damage following falls:</i> Fractures.	Becour, 2013.
Skin	<i>Electrically induced damage:</i> Burns ranging from superficial dot-like lesions to severe extended burn.	Abada et al., 2014; Anders et al., 2003; Burdett-Smith, 1997; Burmatov et al., 2011.
	<i>Indirect damage:</i> Hematomas and abrasions following falls. Severe burns, some fatal (after ignition of fumes or fluids in surroundings).	Becour, 2013; Mangus et al., 2008; Kroll et al., 2017.
Nerves	<i>Electrically induced damage:</i> Lesion of brachial plexus.	Bonnan et al., 2019.
Immune system	<i>Unknown mechanism:</i> Lupus coagulopathy.	Bryant et al., 2014.
Neuro-psychiatry	<i>Electrically induced damage:</i> Agitation and delirium.	Feeney et al., 2010.

ed to an EDW in an attempt to prevent him from doing so after which he fell down on the knife receiving a stab wound in the abdomen (Sharma et al., 2009).

2. Burns

Burns have already been mentioned as a direct consequence of the electrical discharge to the skin, but another situation was described in which the electrical discharge from an EDW ignites an explosive fume or a flammable fluid. One study identified 23 such cases of which ten were classified as major burns (Kroll et al., 2017). Of these, six were fatal. Some involved per-

sons who had soaked their clothes or surroundings in petrol, but one police officer was also killed in an incident where police discharged the EDW inside a house where a person had turned on the natural gas.

3. Aspiration

There is one case study in which a 49-year-old man with several different diseases and severe overweight collapsed during exposure after which he vomited, and the vomit entered the airways. He developed pneumonia and died of multi-organ failure (Plenzig et al., 2021).

Discussion

Tom Swift was the main character in a young adult novel published in 1911, of which one volume was named “Tom Swift and His Electric Rifle”. This imaginary weapon could shoot through walls without leaving a hole, was powerful enough to bring down elephants, rhinoceroses, buffaloes and whales, and saved the life of the protagonist on multiple occasions (Wikipedia, 2024). Sixty years later, the novel gave rise to the name of one of the most commonly used electric discharge weapons, the Taser (Tom Swift and His Electric Rifle), now with an extra A to produce a pronounceable word.

Since then, the real-life Taser and other EDWs have generated intense discussions about their danger. With this literature study, we attempted to compile existing case studies reporting on potential health consequences of EDWs in order to create an overview which we have found missing in the literature.

We have reported on the findings as they have been presented by the authors of the case studies. In some of the cases, in our view a clear direct or at least a very plausible link between the EDW and the injury and harm is presented, for example those where darts and barbs have been found penetrating body parts or where it is clear that an injury occurred at the exact moment of the EDW being fired against a person, like pain arising in a certain muscle group immediately after the incident. However, in other situations the association between EDW use and the mechanism resulting in injury in our view seems more unclear. For example, the association between EDW use and health outcome seems unclear where an underlying disease was seemingly exacerbated by the EDW impact like the reported lupus coagulopathy; where many other reasons for an incident may be present such as the case of an abortion in the first trimester of pregnancy; and where the victim was under the influence of substances that may themselves have contributed to the situation in question.

In no situation has the association between EDWs and adverse health outcomes been more contested than in the case of cardiac incidents. Several severe cases were reported including fatal incidents in very young people. A malignant arrhythmia that causes cardiac arrest will not be identifiable at autopsy. It is therefore not surprising that such cases generate debate about whether the incident could be directly attributed to the EDW discharge and resulting irregular cardiac rhythm. Kroll et al. revisited the cardiac arrests mentioned in the results section here (Kroll et al., 2014). They conclude that many of the case reports confuse a postural collapse or syncope with a cardiac arrest. They also criticize the authors for ignoring literature showing that ventricular fibrillation is only induced if the distance from dart to heart is below a certain limit. Last but not least, they

criticize the authors for not giving any weight to the opinions of the medical examiners who in seven of eight fatal cases did not list the EDW as a primary cause of death. In another retrospective study, Swerdlow et al. collected records from 200 cases of CED-associated, nontraumatic sudden deaths from 2001 to 2008 (Swerdlow et al., 2009). Of those, they only found 56 eligible for further study, and they reviewed available ECGs, video and audio recordings, CED data and autopsies including toxicologic data. In the 144 cases not included in the study, there were no ECGs available, and in only twelve cases did the authors succeed in obtaining records of the initial cardiac rhythm. Based on their findings, the authors concluded that only one case was consistent with electrically induced ventricular fibrillation in which neither drug use nor cardiac disease provided alternative explanations. The authors conclude that their data do not support electrically induced irregular heart rhythms, such as ventricular fibrillation, as a common mechanism of sudden death after CEW discharge, and that the specific mechanisms for most of these deaths remain unknown. The challenges of obtaining decisive information in cases of cardiac arrest are well-known. Where EDWs are involved, we would caution against jumping to the conclusion that EDW discharge did not play a role if no evidence can be found confirming a causal mechanism. In other words, absence of evidence is not evidence of absence. Therefore, in those cases where there is clear evidence of other causal mechanisms, it may be fair to rule out EDW-related cardiac causes of death, but in those where no other explanations can be found, EDW discharge should in our view as a minimum be considered as a potential contributor to death.

In this review, we have focused on case studies to provide as broad a picture as possible of the many potential injury types observed following EDW use. One interesting question is related to the frequency of the different types of injuries, which for obvious reasons cannot be deducted from the cases presented. While this is beyond the scope of this article, an interesting finding from one of the articles reviewed merits attention: One-third of the 48 patients seen in the study by Becour had some kind of injury, albeit often minor such as abrasions (Becour, 2013). This is in line with Strote et al. who found that significant injuries related to six years of law enforcement CEW use in one city were rare (Strote et al., 2010); and findings by Bozeman et al. who found mild or no injuries after CED use in 1198 out of 1201 subjects during three years of law enforcement across six different law enforcement agencies (Bozeman et al., 2009). In the latter study, two subjects experienced intracranial injuries from falls, and one experienced rhabdomyolysis.

Notwithstanding the frequency of adverse effects, severe consequences have been observed following the use of EDWs.

While the nature of a case report does not necessarily allow the establishment of a final causal relationship, the reviewed reports document the following serious consequences of EDW exposure: loss of vision, permanent damage to brain tissue, severe burns requiring skin grafting, incapacitating damage to nerves and tendons, potentially fatal conditions like pneumothorax and renal failure, and even death.

In addition, it needs to be remembered that what is reported in the case studies are mostly incidents where the EDW was used by trained law enforcement agents. For obvious reasons, no studies have been able to show exactly what the outcome is of the use and misuse of the same tools in a torture context where they may be employed with the intention to cause harm, pain and suffering. It is, however, not difficult to imagine that the same or more severe consequences seen elsewhere can be observed in such a context, for example if a person is subjected to EDW application, maybe even repetitive, leading to contraction of muscles and potential falls. Any consequence described in the results section could potentially occur in the case of excessive and unauthorized EDW use, including torture, as well.

Two other topics merit attention in relation to EDWs in the context of torture or ill-treatment: Pain and suffering. There is a glaring absence of descriptions of pain in the case studies described, but it does not take much imagination to envision the pain persons subjected to EDW discharge must feel at the moment of unwillful muscle contraction and electric discharge. Two persons who experienced an EDW discharge as part of certification of training have described the pain as follows (Quora, 2019):

“...getting hit with a metal baseball bat, then an intense tension muscle cramp while being stabbed repeatedly with a pitchfork.”

“The Taser, oh, good Lord; I dropped like a pole-axed mule! EVERY muscle in my body clenched and felt like the worst Charlie horse one could possibly imagine. While the pain was fairly short lived, had I been a perp I would have likely done ANYTHING to avoid a repeat.”

There is also a near-total absence in the case series of descriptions of mental suffering following EDW discharge. Nevertheless, one police officer hit accidentally reported depressed and anxious mood seven months post-incident, and another person reported anxiety, difficulties in concentrating and irritability (Bui et al., 2009; Le Blanc-Louvry et al., 2012). If an EDW is used with the intention to elicit intense fear and pain in the context of torture, it is to be expected that it may lead to anxi-

ety, depression and even post-traumatic stress disorder (PTSD) as documented for other torture methods.

Limitations

Our review was limited by a number of factors. Case studies may have been missed in our search if they did not include the term *case study/report/series* as key word or in the title or abstract. We employed only two search engines and focused on the adverse health effects on adults. Our review does not include a comparative analysis between the effects of contact (such as stun gun) versus projectile (such as Taser) application since reviewed studies did not consistently specify the EDW used or the model. This is further complicated by the fact that Tasers can be employed both by direct contact and via projectile use. Finally, given the nature of this review, statistical associations and frequency cannot be generated and causal relationships cannot be inferred. Case reports are inherently not generalizable and are prone to selection bias.

Conclusions and outlook

Our review aimed to consolidate information from case studies on the range of adverse health outcomes due to the use of EDWs since to our knowledge such a comprehensive overview does not currently exist. The reviewed case reports document cases of loss of vision, permanent damage to brain tissue, severe burns requiring skin grafting, incapacitating damage to nerves and tendons, potentially fatal conditions like pneumothorax and renal failure, and even death following exposure to an EDW. In compiling the range of adverse effects of EDWs one is reminded of the effects of electric torture, the second most common form of torture globally (Liu et al., 2021; Milewski et al., 2023).

EDWs such as Tasers are designed for application on physically and mentally fit persons (Axon Enterprise, Inc., 2018). In reality, it is almost impossible for law enforcement officers to establish this prior to application. Our review of case reports demonstrates that EDWs have led to physical suffering. We posit that EDWs may also result in mental pain and suffering.

As more States adopt EDWs as a means of law enforcement, it is imperative that 1) clinicians assessing patients and documenting cases where EDWs may have been used, including torture and ill-treatment cases, are aware of the different types of potential injury; 2) more representative and rigorous research is conducted on the effects of EDWs to investigate potential causality to physical and mental suffering; 3) The mere fact that EDWs can do harm and induce pain and suffering should lead to considerations about their availability and use. Advocacy efforts are needed to spark discussions among decision-makers about this important topic, including pos-

sible enforcement of obligations to update protocols of use and to publicize potential adverse physical and mental health effects. This includes not only law enforcement but also the general availability in society of these potentially harmful and certainly painful weapons.

References

- Abada, H., Aktouf, A., Delaunay, F., Lievain, L., & Auquit-Auckbur, I. (2014). Alopecia reconstruction by expansion after a scalp burn injury caused by Taser(R): A case report. *Annales de dermatologie et de venerologie*, *141*(12), 769–772. <https://doi.org/10.1016/j.annder.2014.06.012>
- Abdelaty, M., Kandil, M. A., & Walsh, K. (n.d.). Bone-Penetrating TASER Bolt: A Rare Case of Penetrating Injury to the Middle Phalanx of the Little Finger. *Cureus*, *13*(11), e19461. <https://doi.org/10.7759/cureus.19461>
- Al-Jarabah, M., Coulston, J., & Hewin, D. (2008). Pharyngeal perforation secondary to electrical shock from a Taser gun. *Emergency Medicine Journal : EMJ*. <https://doi.org/10.1136/emj.2007.056416>
- Anders, S., Junge, M., Schulz, F., & Puschel, K. (2003). Cutaneous current marks due to a stun gun injury. *J Forensic Sci*, *48*(3), 640–642.
- Axon Enterprise, Inc. (2018). *TASER Handheld CEW Warnings, Instructions, and Information: Law Enforcement*. file:///C:/Users/ma/Downloads/V22%20TASER%20Handheld%20CEW%20Law%20Enforcement%20Warnings.pdf
- Axon Law Enforcement*. (2024). <https://www.axon.com/industries/law-enforcement>
- Baldwin, D. E., Nagarakanti, R., Hardy, S. P., Jain, N., Borne, D. M., England, A. R., Nix, E. D., Daniels, C. L., Abide, W. P., & Glancy, D. L. (2010). Myocardial infarction after taser exposure. *The Journal of the Louisiana State Medical Society : Official Organ of the Louisiana State Medical Society*, *162*(5), 291–292, 294–295.
- Baliatsas, C., Gerbecks, J., Dückers, M. L. A., & Yzermans, C. J. (2021). Human Health Risks of Conducted Electrical Weapon Exposure: A Systematic Review. *JAMA Network Open*, *4*(2), e2037209. <https://doi.org/10.1001/jamanetworkopen.2020.37209>
- Becour, B. (2013). Conducted Electrical Weapons or Stun Guns: A review of 46 cases examined in casualty. *The American Journal of Forensic Medicine and Pathology*, *34*(2), 142–146. <https://doi.org/10.1097/PAF.0b013e31828873d6>
- Belen, E., Tipi, F. F., Bayyigit, A., & Helvacı, A. S. (2015). Acute inferior myocardial infarction after electrical weapon exposure: Case report and review of the literature. *Türk Kardiyol Dern Ars*, *43*(2), 178–181. <https://doi.org/10.5543/tkda.2015.79328>
- Bell, N., Moon, M., & Dross, P. (2013). Cerebrovascular accident (CVA) in association with a Taser-induced electrical injury. *Emergency Radiology*, *21*(2), 211–213. <https://doi.org/10.1007/s10140-013-1180-2>
- Ben Ahmed, H., Bouzouita, K., Selmi, K., Chelli, M., Mokaddem, A., Ben Ameer, Y., & Boujnah, M. (2013). Myocardial infarction after conducted electrical weapon shock. *Ann. Cardiol. Angeiol.*, *62*(2), 124–126. <https://doi.org/10.1016/j.ancard.2012.03.006>
- Bonnan, M., Zerbib, J. L., Barroso, B., Puvilland, L. M., Demasles, S., Marasescu, R., & Krim, E. (2019). Acute brachial plexus lesion complicating a stun-gun assault. *Revue Neurologique*, *175*(1–2), 87–88. <https://doi.org/10.1016/j.neurol.2018.01.374>
- Bozeman, W. P., Hauda, W. E., Heck, J. J., Graham, D. D., Martin, B. P., & Winslow, J. E. (2009). Safety and injury profile of conducted electrical weapons used by law enforcement officers against criminal suspects. *Annals of Emergency Medicine*, *53*(4), 480–489. <https://doi.org/10.1016/j.annemergmed.2008.11.021>
- Bui, Sourkes, & Wennberg. (2009). Generalized tonic-clonic seizure after a taser shot to the head. *CMAJ*, *180*(6), 625–626.
- Burdett-Smith, P. (1997). Stun gun injury. *Emergency Medicine Journal*, *14*(6), 402–404. <https://doi.org/10.1136/emj.14.6.402>
- Burmatov, A. P., Bernatskikh, T. K., Zoroastrov, O. M., Lotter, M. G., Burmatov, N. A., & Zoroastrov, M. O. (2011). Marks on the human and animal skin after contact with an electrical discharge device. *Sudebno-meditsinskaia ekspertiza*, *54*(6), 41–43.
- Campbell, F., & Clark, S. (2019). Penetrating facial trauma from a Taser barb. *The British Journal of Oral & Maxillofacial Surgery*, *57*(2), 188–189. <https://doi.org/10.1016/j.bjoms.2018.12.009>
- Cao, M., Shinbane, J. S., Gillberg, J. M., & Saxon, L. A. (2007). Taser-induced rapid ventricular myocardial capture demonstrated by pacemaker intracardiac electrograms. *J Cardiovasc Electrophysiol*, *18*(8), 876–879. <http://dx.doi.org/10.1111/j.1540-8167.2007.00881.x>
- Chandler, J., Martin, B. P., & Graham, D. D. (2013). TASER(R) injury to the forehead. *J Emerg Med*, *44*(1), e67-8. <https://doi.org/10.1016/j.jemermed.2011.06.009>
- Cheek, S., Shifflette, V., & Dunn, E. (2013). Foreign Body Removal: A Shocking Story. *The American Surgeon*, *79*(1), 35–36. <https://doi.org/10.1177/000313481307900119>
- Chen, S. L., Richard, C. K., Murthy, R. C., & Lauer, A. K. (2006). Perforating ocular injury by Taser. *Clin Exp Ophthalmol*, *34*(4), 378–380. <https://doi.org/10.1111/j.1442-9071.2006.01228.x>
- Coad, F., & Maw, G. (2014). TASERed during training: An unusual scapular fracture. *Australasian College for Emergency Medicine and Australasian Society for Emergency Medicine*, 206–207. <https://doi.org/10.1111/1742-6723.12206>
- Council Of Europe. (2013). *Report to the Russian Government on the visit to the North Caucasian region of the Russian Federation carried out by the European Committee for the Prevention of Torture and Inhuman or Degrading Treatment or Punishment (CPT) from 27 April to 6 May 2011* (CPT/Inf (2013) 1).
- Council Of Europe. (2015). *Report to the Bulgarian Government on the visit to Bulgaria carried out by the European Committee for the Prevention of Torture and Inhuman or Degrading Treatment or Punishment (CPT) from 24 March to 3 April 2014* (CPT/Inf (2015) 12).
- Crawley, K., Taylor, R., & Sandhu, A. (2023). Frontal Sinus Injury Secondary to TASER Dart: A Narrative Review. *Journal of Maxillofacial and Oral Surgery*, *22*(3), 666–668. <https://doi.org/10.1007/s12663-022-01790-7>
- De Courcay, C., & Jones, M. A. (2021). Taser barb penetration causing phalangeal fracture. *BMJ Case Reports*, *14*(5), e240953. <https://doi.org/10.1136/bcr-2020-240953>
- de Runz, A., Minetti, C., Brix, M., & Simon, E. (2014). New TASER injuries: Lacrimal canaliculus laceration and ethmoid

- bone fracture. *Int J Oral Maxillofac Surg*, 43(6), 722–724. <https://doi.org/10.1016/j.ijom.2013.12.006>
- Dearing, M., & Lewis, T. J. (2005). Foreign body lodged in distal phalanx of left index finger-taser dart. *Emerg Radiol*, 11(6), 364–365. <https://doi.org/10.1007/s10140-005-0428-x>
- DeepL SE. (n.d.). *DeepL Translator*. Retrieved April 3, 2024, from <https://www.deepl.com/translator>
- Delavar, B., & Thompson, M. A. (2021). Penetrating Intracranial Taser Injury. *The Journal of Emergency Medicine*, 61(5), 590–591. <https://doi.org/10.1016/j.jemermed.2021.07.071>
- Dunet, B., Erbland, A., Abi-Chahla, M. L., Tournier, C., & Fabre, T. (2015). The TASERed finger: A new entity. Case report and review of literature. *Chir Main*, 34(3), 145–148. <https://doi.org/10.1016/j.main.2015.04.001>
- England, J., Brown, W., & Dearn, J. (2015). Sudden cardiac arrest associated with application of shocks from a TASER Electronic Control Device. *Heart Lung and Circulation*, 24(SUPPL. 3), S230. <http://dx.doi.org/10.1016/j.hlc.2015.06.284>
- European Council. (2011, December 21). *Council Regulation (EC) No 1236/2005 of 27 June 2005 concerning trade in certain goods which could be used for capital punishment, torture or other cruel, inhuman or degrading treatment or punishment, CELEX1* [Website]. <https://publications.europa.eu/en/publication-detail/-/publication/e7749622-48ca-4339-a7e0-92b363c975cb/language-en>
- Feeney, C., Vu, J., & Ani, C. (2010). Acute Agitated Delirious State Associated With Taser Exposure. *Journal of the National Medical Association*, 102(12), 1254–1257.
- Gapsis, B. C., Hoang, A., Nazari, K., & Morcos, M. (2017). Ocular manifestations of TASER-induced trauma. *Trauma Case Rep*, 12, 4–7. <https://doi.org/10.1016/j.tcr.2017.10.001>
- Gardner, A. R., Hauda, W. E., & Bozeman, W. P. (2012). Conducted electrical weapon (TASER) use against minors: A shocking analysis. *Pediatric Emergency Care*, 28(9), 873–877. <https://doi.org/10.1097/PEC.0b013e31826763d1>
- Giaconi, J., Ries, M., & Steinbach, L. (2011). Stun gun induced myotendinous injury of the iliopsoas and gluteus minimus. *Journal of the International Skeletal Society A Journal of Radiology, Pathology and Orthopedics*, 40(6), 783–787. <https://doi.org/10.1007/s00256-011-1105-7>
- Gleason, J. B., & Ahmad, I. (2015). TASER® Electronic Control Device-Induced Rhabdomyolysis and Renal Failure: A Case Report. *Journal of Clinical and Diagnostic Research : JCDR*, 9(10), HD01–HD02. <https://doi.org/10.7860/JCDR/2015/15465.6608>
- Gross, E., Porterieko, J., & Joseph, D. (2013). *Rhabdomyolysis and Oliguric Renal Failure after Use of TASER: Is It Really Safe?* (Vol. 79).
- Haegeli, L. M., Sterns, L. D., Adam, D. C., & Leather, R. A. (2006). Effect of a Taser shot to the chest of a patient with an implantable defibrillator. *Heart Rhythm*, 3(3), 339–341. <http://dx.doi.org/10.1016/j.hrthm.2005.12.012>
- Han, J. S., Chopra, A., & Carr, D. (2009). Ophthalmic injuries from a TASER. *CJEM*, 11(01), 90–93. <https://doi.org/10.1017/S1481803500010976>
- Hinchey, P. R., & Subramaniam, G. (2009). Pneumothorax as a complication after TASER activation. *Prehospital Emergency Care : Official Journal of the National Association of EMS Physicians and the National Association of State EMS Directors*, 13(4), 532–535. <https://doi.org/10.1080/10903120903144890>
- Holder, E. H., Robinson, L. O., Laub, J. H., & MacDonald, J. (2011). *Police use of force: Tasers and other less-lethal weapons*. National Institute of Justice. <http://dx.doi.org/10.13140/RG.2.1.5100.4647>
- Hudak, L. A., Marti, J. J., & Houry, D. E. (2011). Bilateral patellar tendon rupture after stun gun shock. *Injury Extra*, 42(11), 186–188. <https://doi.org/10.1016/j.injury.2011.06.421>
- Jenkinson, E., Neeson, C., & Bleetman, A. (2006). The relative risk of police use-of-force options: Evaluating the potential for deployment of electronic weaponry. *J Clin Forensic Med*, 13(5), 229–241. <https://doi.org/10.1016/j.jcfm.2005.11.006>
- Jey, A., Hull, P., Kravchuk, V., Carillo, B., & Martel, J. B. (2016). Emergent diagnosis and management of TASER penetrating ocular injury. *The American Journal of Emergency Medicine*, 34(8), 1740.e3–1740.e5. <https://doi.org/10.1016/j.ajem.2016.01.005>
- Kim, P. J., & Franklin, W. H. (2005). Ventricular Fibrillation after Stun-Gun Discharge. *The New England Journal of Medicine*, 353(9), 958–959. <https://doi.org/10.1056/NEJMc051625>
- Koscove, E. M. (1987). Taser® dart ingestion. *The Journal of Emergency Medicine*, 5(6), 493–498. [https://doi.org/10.1016/0736-4679\(87\)90212-5](https://doi.org/10.1016/0736-4679(87)90212-5)
- Kroll, M. W., Adamec, J., Wetli, C. V., & Williams, H. E. (2016). Fatal traumatic brain injury with electrical weapon falls. *J Forensic Leg Med*, 43, 12–19. <https://doi.org/10.1016/j.jflm.2016.07.001>
- Kroll, M. W., Lakkireddy, D. R., Stone, J. R., & Luceri, R. M. (2014). TASER Electronic Control Devices and Cardiac Arrests: Coincidental or Causal? *Circulation*, 129(1), 93–100. <https://doi.org/10.1161/CIRCULATIONAHA.113.004401>
- Kroll, M. W., Ritter, M. B., & Williams, H. E. (2017). Fatal and non-fatal burn injuries with electrical weapons and explosive fumes. *J Forensic Leg Med*, 50, 6–11. <https://doi.org/10.1016/j.jflm.2017.06.001>
- Kunz, S., Ho, J., Dawes, D., & Knack, S. (2024). Effectiveness of a New-Generation CEW in Human Subjects with a Goal-Directed Task. *Human Factors and Mechanical Engineering for Defense and Safety*, 8. <https://doi.org/10.1007/s41314-024-00066-x>
- Le Blanc-Louvry, I., Gricourt, C., Touré, E., Papin, F., Proust, B., Le Blanc-Louvry, I., Gricourt, C., Touré, E., Papin, F., & Proust, B. (2012). A brain penetration after Taser injury: Controversies regarding Taser gun safety. *Forensic Sci Int*, 221(1–3), e7–11. <https://doi.org/10.1016/j.forsciint.2012.03.027>
- Lee, B. K., Vittinghoff, E., Whiteman, D., Park, M., Lau, L. L., & Tseng, Z. H. (2009). Relation of Taser (electrical stun gun) deployment to increase in in-custody sudden deaths. *The American Journal of Cardiology*, 103(6), 877–880. <https://doi.org/10.1016/j.amjcard.2008.11.046>
- Lewis, M. C., & Lewis, D. E. (2016). Frontal Sinus TASER Dart Injury. *The Journal of Emergency Medicine*, 50(3), 490–492. <https://doi.org/10.1016/j.jemermed.2015.09.024>
- Li, J. Y., & Hamill, M. B. (2013). Catastrophic Globe Disruption as a Result of a TASER Injury. *The Journal of Emergency Medicine*, 44(1), 65–67. <https://doi.org/10.1016/j.jemermed.2011.03.010>
- Liu, C., Kakalis, M., & Weintraub, J. (2021). *Torture by*

- administration of electric shocks: The case of PG (Vol. 31).
- Lokdam, N., Hincheli, N. L., & Aon, M. (2018). *DIGNITY Fact Sheet Collection, Health #3: Electric Discharge Weapons (EDWs)*. <https://dignity.dk/wp-content/uploads/electric-discharge-weapons-factsheet-english.pdf>
- Maher, P. J., Beck, N., Strote, J., & Med, J. (2015). Pneumomediastinum and pulmonary interstitial emphysema after tracheal taser injury. *Emergency Medicine Journal : EMJ*, 32(1), 90. <https://doi.org/10.1136/emmermed-2013-203160>
- Mangus, B. E., Shen, L. Y., Helmer, S. D., Maher, J., & Smith, R. S. (2008). Taser and Taser associated injuries: A case series. *The American Surgeon*, 74(9), 862–865.
- Mansueto, G., Di Napoli, M., Mascolo, P., Carfora, A., Zangani, P., Pietra, B. D., & Campobasso, C. P. (2021). Electrocutation Stigmas in Organ Damage: The Pathological Marks. *Diagnostics (Basel, Switzerland)*, 11(4), 682. <https://doi.org/10.3390/diagnostics11040682>
- Mehl, L. E. (1992). Electrical injury from taser and miscarriage. *Acta Obstetrica et Gynecologica Scandinavica*. <https://www.tandfonline.com/doi/abs/10.3109/00016349209007967>
- Milewski, A., Weinstein, E., Lurie, J., Lee, A., Taki, F., Pilato, T., Jedlicka, C., & Kaur, G. (2023). Reported Methods, Distributions, and Frequencies of Torture Globally: A Systematic Review and Meta-Analysis. *JAMA Network Open*, 6(10), e2336629. <https://doi.org/10.1001/jamanetworkopen.2023.36629>
- Moysidis, S. N., Koullisis, N., Rodger, D. C., Chao, J. R., Leng, T., de Carlo, T., Burkemper, B., Ediriwickrema, L. S., George, M. S., Jiang, Y., Bohm, K. J., Gulati, S., Torres, R. J., Meallet, M. A., Moshfeghi, A. A., Flynn, H. W., Mieler, W. F., Williams, G. A., Humayun, M. S., & Elliott, D. (2019). Thomas A. Swift's Electric Rifle Injuries to the Eye and Ocular Adnexa: The Management of Complex Trauma. *Ophthalmology. Retina*, 3(3), 258–269. <https://doi.org/10.1016/j.oret.2018.10.005>
- Multerer, S., Berkenbosch, J. W., Das, B., & Johnsrude, C. (2009). Atrial fibrillation after taser exposure in a previously healthy adolescent. *Pediatric Emergency Care*, 25(12), 851–853. <https://doi.org/10.1097/PEC.0b013e3181c399a9>
- Naunheim, R. S., Treaster, M., & Aubin, C. (2010). Ventricular fibrillation in a man shot with a Taser. *Emergency Medicine Journal*, 27(8), 645–646. <https://doi.org/10.1136/emj.2009.088468>
- Ng, W., & Chehade, M. (2005). Taser penetrating ocular injury. *Am J Ophthalmol*, 139(4), 713–715. <https://doi.org/10.1016/j.ajo.2004.11.039>
- NIJ. (2009, August 3). *The Use-of-Force Continuum*. National Institute of Justice. <https://nij.ojp.gov/topics/articles/use-force-continuum>
- Paninski, R. J., Marshall, M. E., & Link, M. S. (2013). ICD Oversensing Caused by TASER. *Journal of Cardiovascular Electrophysiology*, 24(1), 101–101. <https://doi.org/10.1111/jce.12046>
- Plenzig, S., Verhoff, M. A., Gruber, H., & Kunz, S. N. (2021). Aspiration-related pneumonia after Taser exposure – A multiple causations mechanism. *Forensic Science International (Online)*, 326. <https://doi.org/10.1016/j.forsciint.2021.110906>
- Pope, T. D., Japra, N., Shah, A. D., & Lloyd, M. (2023). Real-time monitoring of an implantable cardiac device during taser device discharge. *HeartRhythm Case Reports*, 9(6), 420–422. <https://doi.org/10.1016/j.hrcr.2023.03.020>
- Quora. (2019). *How much does a taser hurt really?* Quora. <https://www.quora.com/How-much-does-a-taser-hurt-really>
- Rafailov, L., Temnograd, J., Tsai, F. F., & Shinder, R. (2017). Impaled Orbital TASER Probe Injury Requiring Primary Enucleation. *Ophthalmic Plastic & Reconstructive Surgery*, 33(3S), S176–S177. <https://doi.org/10.1097/IOP.0000000000000486>
- Rehman, T. U., Yonas, H., & Marinaro, J. (2007). Intracranial penetration of a TASER dart. *American Journal of Emergency Medicine*, 25(6), 733.e3-4. <https://doi.org/10.1016/j.ajem.2006.12.017>
- Richards, K. A., Kleuser, L. P., & Kluger, J. (2008). Fortuitous therapeutic effect of Taser shock for a patient in atrial fibrillation. *Ann Emerg Med*, 52(6), 686–688. <https://doi.org/10.1016/j.annemergmed.2008.04.023>
- Sanford, J. M., Jacobs, G. J., Roe, E. J., & Terndrup, T. E. (2011). Two patients subdued with a TASER(R) device: Cases and review of complications. *The Journal of Emergency Medicine*, 40(1), 28–32. <https://doi.org/10.1016/j.jemermed.2007.10.059>
- Sayegh, R., Madsen, K., Adler, J., Johnson, M., & Mathews, M. (2011). Diffuse retinal injury from a non-penetrating TASER dart. *The Journal of Clinical Electrophysiology and Vision - The Official Journal of the International Society for Clinical Electrophysiology and Vision*, 123(2), 135–139. <https://doi.org/10.1007/s10633-011-9287-9>
- Schwarz, E. S., Barra, M., & Liao, M. M. (2009). *Successful resuscitation of a patient in asystole after a TASER injury using a hypothermia protocol*. (Vol. 27). <https://doi.org/10.1016/j.ajem.2008.07.042>
- Semple, T., Jenkins, B., & Bennell, C. (2021). *Injuries and deaths proximate to oleoresin capsicum spray deployment: A literature review*. <https://journals-sagepub-com.ezproxy.aub.edu.lb/doi/10.1177/0032258X20926873>
- Seth, R. K., Abedi, G., Daccache, A. J., & Tsai, J. C. (2007). Cataract secondary to electrical shock from a Taser gun. *Journal of Cataract and Refractive Surgery*. <https://doi.org/10.1016/j.jcrs.2007.04.037>
- Sharabura, A. B., Fong, J. W., & Pemberton, J. D. (2021). Ocular TASER Probe Injury Managed with Primary Evisceration: Case Report. *Case Reports in Ophthalmology*, 12(3), 934–939. <https://doi.org/10.1159/000520460>
- Sharma, A., Theivacumar, N. S., & Souka, H. M. (2009). Tasers—Less than lethal! *Ann R Coll Surg Engl*, 91(4), W20-1. <https://doi.org/10.1308/147870809x400958>
- Sheppard, K. G., & Welsh, B. C. (2022). Can police use of less-than-lethal weapons reduce harm during violent police-citizen encounters? A systematic review and directions for future research. *Aggression and Violent Behavior*, 64, 101748. <https://doi.org/10.1016/j.avb.2022.101748>
- Sloane, C. M., Chan, T. C., & Vilke, G. M. (2008). Thoracic Spine Compression Fracture After TASER Activation. *The Journal of Emergency Medicine*, 34(3), 283–285. <http://dx.doi.org/10.1016/j.jemermed.2007.06.034>
- Strote, J., Walsh, M., Angelidis, M., Basta, A., & Hutson, H. R. (2010). Conducted Electrical Weapon Use by Law Enforcement: An Evaluation of Safety and Injury. *The Journal of*

- TRAUMA Injury Infection and Critical Care*, 68(5), 1239–1246. <https://doi.org/10.1097/TA.0b013e3181b28b78>
- Swerdlow, C. D., Fishbein, M. C., Chaman, L., Lakkireddy, D. R., & Tchou, P. (2009). Presenting rhythm in sudden deaths temporally proximate to discharge of TASER conducted electrical weapons. *Acad Emerg Med*, 16(8), 726–739. <https://doi.org/10.1111/j.1553-2712.2009.00432.x>
- Takats, S., Stillman, D., Cheslack-Postava, F., Bagdonas, M., Jullinek, A., Najdek, T., Petrov, D., Rentka, M., & Venčkauskas, A. (2023). *Zotero (6.0.26) [Windows 10]*. <https://www.zotero.org/> [Computer software]. Corporation for Digital Scholarship.
- Terrill, W., & Paoline, E. A. (2012). Conducted Energy Devices (CEDs) and Citizen Injuries: The Shocking Empirical Reality. *Justice Quarterly*, 29(2), 153–182. <https://doi.org/10.1080/07418825.2010.549834>
- Teymoorian, S., San Filippo, A. N., Poulouse, A. K., & Lyon, D. B. (2010). Perforating globe injury from Taser trauma. *Ophthalmic Plast Reconstr Surg*, 26(4), 306–308. <https://doi.org/10.1097/IOP.0b013e3181c15c36>
- Theisen, K., Slater, R., & Hale, N. (2016). Taser-Related Testicular Trauma. *Urology*, 88, e5. <https://doi.org/10.1016/j.urology.2015.11.011>
- Tyagi, A., Gill, A., & Felton, B. (2017). Thoracic Compression Fracture as a Result of Taser® Discharge. *Clinical Practice and Cases in Emergency Medicine*, 1(4), 319–322. <https://doi.org/10.5811/cpcem.2017.7.33508>
- UNCAT. (2008). *Conclusions and recommendations of the United Nations Committee against Torture: Portugal (CAT/C/PRT/CO/4)*. <https://www.refworld.org/docid/4804a62e.html>
- UNCAT. (2018). *Concluding observations on the seventh periodic report of the Netherlands adopted by the United Nations Committee against Torture at its sixty-fifth session (12 November-7 December 2018)*. <https://documents.un.org/doc/undoc/gen/g18/442/89/pdf/g1844289.pdf?token=H6z7MrHMmGPFFIZpl3&fe=true>
- Wikipedia. (2024). Tom Swift and His Electric Rifle. In *Wikipedia*. https://en.wikipedia.org/w/index.php?title=Tom_Swift_and_His_Electric_Rifle&oldid=1210275379
- Willoughby, L., Peyton, K., Gorgas, D., & Li-Sauerwine, S. (2022). Leveraging Resources to Remove a Taser Barb Embedded in Bone: Case Report. *Clinical Practice and Cases in Emergency Medicine*, 6(1), 41–43. <https://doi.org/10.5811/cpcem.2021.10.54196>
- Winslow, J. E., Bozeman, W. P., Fortner, M. C., & Alson, R. L. (2007). Thoracic Compression Fractures as a Result of Shock From a Conducted Energy Weapon: A Case Report. *Annals of Emergency Medicine*, 50(5), 584–586. <https://doi.org/10.1016/j.annemergmed.2007.06.008>
- Zipes, D. P. (2013). *Response to Letters Regarding Article, “Sudden Cardiac Arrest and Death Following Application of Shocks From a TASER Electronic Control Device” (Vol. 127)*. <https://doi.org/10.1161/CIRCULATIONAHA.112.147520>

Submitted 5th of April 2024

Accepted 24th of April 2024