

3

CHRONOLOG

2026

ARCHAEOLOGY, ASSYRIOLOGY, & EGYPTOLOGY



Reconstructing Irtysenu: From 19th Century Autopsy to 21st Century Discovery

Alma Foldbjerg El-Naaman

Abstract

Ancient Egyptian mummified individuals can offer valuable insights into history. This article will focus on the case of Irtysenu, Lady of the House, also known as Dr. Granville's Mummy, trying to reconstruct her journey from her first autopsy in 1821 by Dr. Augustus Bozzi Granville to recent examinations through a literature review. Irtysenu has undergone multiple tests aiming to determine her cause of death, age, and race, among other factors. But how much new information can modern methods like ancient DNA analysis and X-ray provide? As this paper traces Irtysenu's story over the past 200 years, it shows how new technologies can reveal fresh details about her health and disease, changing her originally identified cause of death from an ovarian tumor to pulmonary tuberculosis, and exploring potential reasons for her weight loss, offering further insights into her overall health.

Keywords: Funerary practices; palaeopathology; Egypt; ethical practice; morphology

Alma Foldbjerg El-Naaman

MA Near Eastern

Archaeology, UCPH

BA in Near Eastern

Archaeology, UCPH

BA in Egyptology, UCPH

Contact

Almaelnaaman@gmail.com

Interest areas

Ancient Egyptian funerary rituals, mummy studies, paleopathology, parasites, and digital methods

يمكن للأفراد المحنطين في مصر القديمة أن يوفرنا رؤى قيمة حول التاريخ. تركز هذه المقالة على حالة إرتيسينو، سيدة البيت، المعروفة أيضاً بمومياء الدكتور جرانفيل، محاولة إعادة بناء رحلتها من تشريحها الأول عام 1821 من قبل الدكتور أوغسطس بوتسي جرانفيل إلى الفحوصات الحديثة من خلال استعراض الدراسات السابقة. خضعت إرتيسينو لعدة اختبارات بهدف تحديد سبب وفاتها وعمرها وعرقها، من بين عوامل أخرى. لكن ما مقدار المعلومات الجديدة التي يمكن للطرق الحديثة مثل تحليل الحمض النووي القديم والأشعة السينية أن توفرها؟ تتتبع هذه الورقة قصة إرتيسينو على مدى 200 عام الماضية، مظهرة كيف يمكن للتقنيات الجديدة أن تكشف تفاصيل جديدة عن صحتها ومرضها، مما غيّر سبب الوفاة المحدد أصلاً من ورم المبيض إلى السل الرئوي، واستكشاف الأسباب المحتملة لفقدان وزنها، مما يوفر رؤى إضافية حول صحتها العامة.

Translation by
Mahmoud Alsayed Ahmed,
MA-student, UCPH

Introduction

The obsession with ancient Egyptian history and culture is far from new, having been a fascination since the Romans, continuing into recent days, and is today known as 'Egyptomania'. Egyptomania has had many waves, and during the 18th and 19th centuries, Egyptian mummies sparked considerable curiosity. During this time, mummy unwrapping parties were viewed as a unique form of entertainment. From mummy unwrappings to mummies being used as paint and medicine, many Egyptian mummies were destroyed and knowledge lost as the unwrappings and other usage of Egyptian mummies were rarely documented (Lambert et al., 2018: 6). The ethical concerns surrounding ancient human remains today were rarely considered as these mummies were consistently not recognized as deceased human beings and instead seen as objects (Grauer, 2018; Ikram, 2020; Ikram and Dodson, 1998: 72-73). However, there were a few exceptions to this. One of these exceptions was Irtysenu, who underwent one of the first known scientific mummy autopsies in 1821 under the hands of Dr. Augustus Bozzy Granville (Donoghue et al., 2010; Pain, 2008: 72-73; 2016). In the following years, many would continue to perform more scientific autopsies to learn about the lives of the ancient Egyptians (David, 2008a; Ikram, 2020; Murray, 1910; Pettigrew, 1837; Villa et al., 2015).

This article will focus on the mummified remains of Irtysenu, Lady of the House, also known as Dr. Granville's Mummy, and will reconstruct her journey through the last 200 years through a literature review. While doing so, the article will explore the evolving methods and ethical concerns surrounding the examination of ancient human remains and how these methods can provide new insights into health and disease. To illustrate these points, pictures of the original drawings from Dr. Granville's report will be included to support the discussion. This will consist of drawings of human remains.

The Discovery of Irtysenu

In Gurna, Egypt, on the 24th of March in 1819, the mummified remains of a woman, whose name and title would later be identified as Irtysenu, Lady of the House, were purchased by Sir Archibald Edmonstone, 3rd Baronet, for about four dollars (Granville, 1825: 269; Pain, 2008: 72-73). Edmonstone was a patient of Dr. Augustus Bozzy Granville (1783-1872), who was a well-known gynecologist and surgeon, and to whom Edmonstone gifted the remains of Irtysenu. Dr. Granville was a well-travelled doctor, who had practiced medicine in many countries, such as Turkey, Spain, Portugal, and Greece, where he also had contracted different diseases himself, such as the bubonic plague, yellow fever, and malaria. He further developed a great interest in Egyptian mummies and a wish to learn how they mummified their dead (Granville 1825; 1833; Nunn et al. 2000:147-149; Pain 2008: 72-73).

Dr. Granville conducted one of the first scientifically documented autopsies on the mummified remains of Irtysenu, but she was the only Egyptian mummy he dissected (Granville, 1825; Pain, 2008: 72-73). He suggested the cause of death of Irtysenu was 'ovarian dropsy', which is a type of ovarian cyst (Granville, 1825; 1833; Nunn et al.,

Reconstructing Irtysenu

2000). 30 years later, the mummified remains of Irtysenu were purchased by the British Museum, where she remained in their storage for more than 100 years until she was reexamined by Egyptologist John Taylor in the late 1980s (Harer et al., 2014). Unfortunately, after Dr. Granville had carried out the original examination of the body, not much remained.

What remains of Irtysenu is today located at the British Museum. This includes a section of her femur, parts of her abdomen, and several organs: the gallbladder, lungs, heart, uterus, and ovaries, to name a few. Located with her remains is also wax, bitumen, and various wrappings and other textiles, which were left in their coffin after the autopsy.

Furthermore, Dr. Granville included a dissected arm from a 'North African' mummy and parts of four human fetuses he used for experimental mummification (British Museum, 2026b; Riggs 2016, p. 217). However, a name and a title were present on the coffin, namely Irtysenu, Lady of the House, which potentially could match the female mummy inside the coffin (Figure 1; Pain, 2008: 72-73).

However, there have been many cases of ancient Egyptian mummies and coffins being switched, possibly matching a better-preserved mummy with a better-preserved coffin, as seen, for instance, with a male mummy being sold in a female coffin and vice versa (Vandenbeusch et al., 2021), but this will be discussed in a later section.

The Original Mummy Autopsy by Dr. Granville

The autopsy of Irtysenu began on the 21st of August 1821 and continued for the next six weeks in the drawing room of Dr. Granville in London. In contrast to other mummy unwrappings in the 19th century, which had little to no documentation, Dr. Granville only invited various prominent people of the time to observe the procedure and provided detailed documentation of all of findings in a final report (Clinker, 2024: 110-111; Riggs, 2016: 113). The report itself started by describing all exterior findings, such as her wrappings and decorations, before turning to the surgical blade, choosing to 'sacrifice a most complete specimen of the Egyptian art of embalming' (Granville, 1825: 281) to fulfill his inquiry of the state of preservation of her body (Granville, 1825).



Figure 1: A picture of the coffin of Irtysenu today (left) and a drawing of the coffin from 1825 (right).

© British Museum, 2026a (left) and Granville, 1825 (right)

Reconstructing Irtysenu

Dr. Granville described the mummy wrappings as having been applied with surgical precision to each limb (Granville, 1825: 271-274). After removing the wrappings, Dr. Granville identified the sex of the individual as female, based on the remains of the breast tissue, as seen in Figure 2 in between her arms (Granville, 1821: 277). He did not find any ventral incision, but, when opening the abdomen, Dr. Granville found evidence that the large intestines had been extracted through the anus (Granville, 1833: 240-241). In contrast to many other Egyptian mummies, whose organs were removed and placed in canopic jars, most of the organs in this mummy were still in situ. The teeth were described as perfectly white and in good condition (Granville, 1825: 275). When unwrapping the body, Dr. Granville found that she had multiple deep wrinkles in the abdomen area (Figure 2), which made him conclude that Irtysenu must have been obese in life, and therefore of a higher status, since an extensive food resource would have been required for obesity (Granville, 1825: 277). During the autopsy, all organs were removed and inspected (Granville, 1825: 296). Dr. Granville decided to saw the cranium in half, horizontally, whereafter he concluded that the brain must have been removed through the nostrils due to damage to the nasal cavity (Granville, 1825: 296-297). During the autopsy, Dr. Granville found an ovarian 'dropsy' (cyst), which he concluded must have been the cause of death since it appeared to have destroyed the structural arrangement of the organ, developing into a large mass of diseased tissue (Granville, 1825: 298-300).

Age at Death Estimation

During Dr. Granville's examination of Irtysenu, he examined the pelvis, noting that Irtysenu must have reached sexual maturity and possibly given birth, based on the morphological changes he observed (Granville, 1825: 298-300). He later concluded that she must have been between 50 and 55 years old at the time of her death (Granville, 1825: 298). This conclusion was based solely on the thinning of the osseous plates in the ilium, which is the uppermost part of the pelvis. To his knowledge, this meant that the person was more than 40 years old, as he believed that the thinning of the osseous plates would gradually worsen until reaching their maximum around 55 years of age (Granville, 1825: 298-299). Today, the thinning of the osseous plates is defined as a characteristic of conditions such as osteoporosis, which is described as low bone mass and deterioration (Cianferotti et al, 2013: 7). This type of osteoporosis can develop due to age or menopause, which could be the case for Irtysenu (Cianferotti et al., 2013: 11-13). Measurements of the long bones, as well as drawings of the pelvis, sacrum, and lower vertebrae, were included in the original autopsy report, which confirms that Irtysenu must have reached adulthood (Figure 3; Granville, 1825: 278, 280, 290).

Today, when doing age estimations, dental development and wear, as well as various elements of the pelvis, are often used. However, since neither the teeth nor the pelvis was preserved after the original autopsy, it is only possible to classify Irtysenu as an adult above 18 years of age (AlQahtani et al., 2010; Buckberry & Chamberlain, 2002; Lovejoy et al., 1985).

Racial Theories

During the 18th and 19th centuries, many racial theories concluded that the ancient Egyptians must have been of Caucasian or European descent, as people of African descent were considered lower-status human beings (Riggs, 2016: 125). In Dr. Granville's examinations of Irtysenu, he could only confirm this theory by using comparative anatomy. He did this by examining the pelvis (Figure 3), which he believed to present the most significant racial difference in women. After the examination, he concluded that the pelvis of Irtysenu was more similar to that of Caucasian or European women, as the appearance and measurements did not match the pelvis he had of a young, black woman in his office (Granville, 1825: 279). This claim was further supported by Dr. Granville's former teacher in medicine, Dr. Cuvier, who had greater experience in the examination of Egyptian mummies and believed the ancient Egyptians had Caucasian origins (Granville, 1825: 281).

This belief that ancient Egyptians were Caucasian or of European descent reflected the prevailing racial theories of the time and was supported by depictions of the 'four races' in multiple New Kingdom tombs (Cornelius, 2010: 325; Riggs, 2016: 125). The 'four races' depict Egyptians, Asians, Nubians, and Libyans with distinct skin tones, clothing, and hairstyles. Here, the Nubians are depicted with dark skin, while the Egyptians are depicted with reddish-brown skin, which was seen as an indicator of their Caucasian heritage (Cornelius, 2010: 325). Today, the claim that ancient Egyptians are descendants of Europeans or Caucasians has been disproven.

Modern researchers use other methods to estimate sex, age, and race, such as sexual dimorphic traits of the skull and pelvis, age-related dental development and dental wear, and bone fusion and morphological differences in the skull for possible race (Riggs, 2016).

Dating the Mummified Remains of Irtysenu

Dr. Granville had numerous theories about when Irtysenu had been alive. However, these were mostly based on his own imagination combined with the information available to him, such as the accounts provided by Herodotus (Granville, 1825: 277, 303, 315). The first suggested dating was that Irtysenu had been alive before the pyramid of Memphis had been built (Granville, 1825: 177). The second suggested dating was that Irtysenu was alive during the reign of Sesostri the Great (Granville, 1825: 315).

In the present day, it is known that the pyramids of Memphis (Giza) were built during the Old Kingdom (2675-2130 BCE), and the king described by Herodotus, Sesostri the Great, is believed to be a combination of Senwosret I (1920-1875 BCE) and Senwosret III (1878-1839 BCE), two great Middle Kingdom (1980-1630 BCE) pharaohs (Dieleman, 2010: 441; Herodotus: II, 102). In 1821, the understanding of ancient Egyptian history was limited.

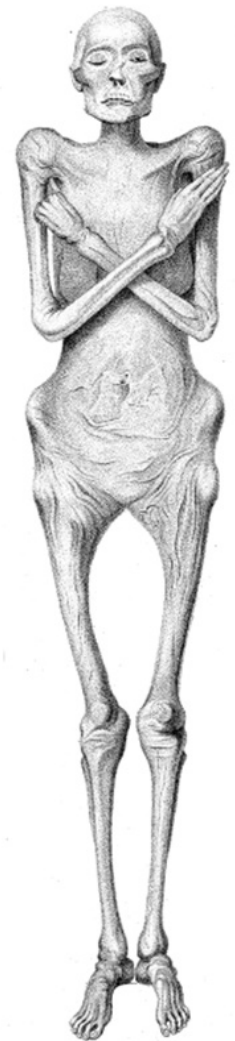

Figure 2: *Drawing of Irtysenu after unwrapping.*

© Granville, 1825: plate XIX.

Reconstructing Irtysenu

However, it is also important to note that Dr. Granville was neither an Egyptologist nor an archeologist but merely an enthusiast and curious surgeon and gynecologist who took great interest in the mummification process (Granville, 1825: 313; Pain, 2008: 72-73).

In modern times, both the iconography of the coffin and the description of the mummification process, as well as radiocarbon dating, have been used to provide a more exact dating. Radiocarbon dating of the coffin wood and mummy linen was performed by Hedges et al. (1997) and yielded dates of around 584 to 490 BCE \pm 50-60 years, respectively, assigning the objects to the Late Period (circa 664-332 BCE), approximately 2000 years later than what Dr. Granville suggested (Hedges et al., 1997: 255-256). This is further supported by the shape and decoration of the coffin, which are characteristic of the Late Period (Dawson, 1925: 76-77). Nonetheless, as mentioned above, there have been many cases of ancient Egyptian mummies and coffins being switched (Vandenbeusch et al., 2021).

However, the mummification characteristics, described by Dr. Granville, consists with the Late Period, such as no body paint evident on the body (Granville 1825, p. 277), the eyes being untouched (Granville 1825, pp. 297-298), the skull shows evidence of the brain having been removed through the nostrils (Granville 1825, p. 297), and although there was no evidence of a ventral incision, there is evidence of the large intestines being removed through the anus (Granville 1825, pp. 307-308), leaving many of the organs in situ (David, 2008b: 16-17).

Therefore, although the coffin matches the biological sex of the mummified individual as well as the time period, it cannot be certain that they belong together, especially today, when neither is fully preserved.

The Mummification of Irtysenu

The mummification technique used on the mummified remains of Irtysenu was compared to the mummification processes described by Herodotus multiple times in the original autopsy report (Granville, 1825: 274, 303, 312; Herodotus: II 86-88). Herodotus (484-425 BCE) was a Greek historian who described many ancient Egyptian medical practices when he visited Egypt around 450 BCE during the Late Period. Here, Herodotus described three ways of mummifying: the expensive one, which included

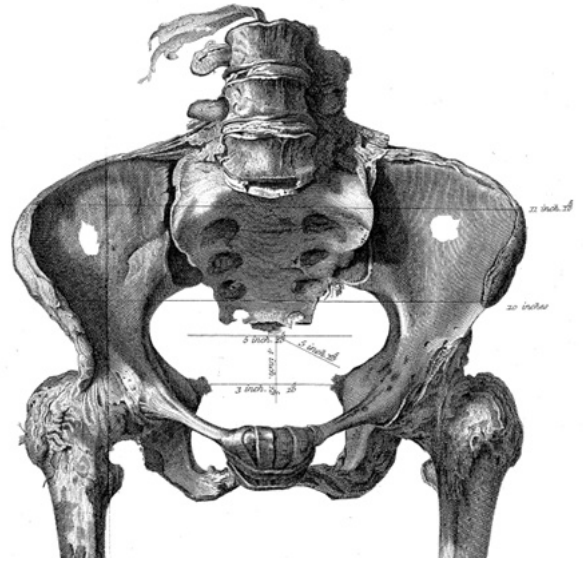


Figure 3. Drawing of the pelvis.
© Granville, 1825: plate XX.

Reconstructing Irtysenu

removal of the brain, evisceration through an incision along the side, a cleansing of the body cavity and the body itself, including submersion in natron for 70 days before being wrapped (Herodotus: II 86).

The middle way included filling the abdomen with cedar-wood oil from syringes for an unknown number of days to dissolve the organs, then emptying it and submerging it in natron. The middle way had no cuts to the body and no wrapping (Herodotus: II 87). The third and least expensive way involved cleansing the abdomen with a purge and submersion in natron for 70 days, without wrapping or cutting the body (Herodotus: II 88).

Dr. Granville noted that Irtysenu must have undergone another form of mummification than the ones described by Herodotus, due to the lack of ventral incision, the use of anal extraction of the organs while also leaving some of the organs in situ, as well as the use of both cotton and linen in the wrapping of Irtysenu. However, Herodotus recorded a mummification method more similar to that of Irtysenu, in which oils were injected, and the intestines were left untouched (Granville, 1825: 274, 312). It is important to note that Herodotus' visit to Egypt would have been approximately 150 years after Irtysenu's mummification, and it is possible that practices changed over time (Brier, 2004: 19; Granville, 1825: 312; Herodotus: II 86-88).

Potential Causes of Death

Since the original cause of death of Irtysenu was determined to be an ovarian cyst by Dr. Granville, Irtysenu has undergone newer examinations for malaria and tuberculosis, two diseases that were prevalent in ancient Egypt (Brier, 2014; Dryer, 2010: 29-32). The potential causes of death are elaborated below.

The Ovarian Cyst

Following the rediscovery of the remains of Irtysenu in the 1980s resulted in the re-examination of the ovarian cyst, now using new techniques that have been developed since the original autopsy in 1821 (Harer et al., 2014: 102). In 1992, Harer et al. (2014) reinvestigated the original proposed cause of death of Irtysenu. Here they focused their examination on the uterus, tubes, and ovaries in order to reexamine the ovarian cyst (Harer et al., 2014). There is generally two types of ovarian cysts: (1) physiological ovarian cysts, caused by normal function of the ovary and are the most common type. This type of cyst has to become larger than a grapefruit before producing symptoms; and (2) neoplastic ovarian cysts, which are categorized as abnormal growth not related to the normal function of the ovaries. This type of cysts is less common and more likely to be malignant, meaning they can be more fatal (Neighbors et al. 2010, pp. 367-368).

The team managed to locate the ovarian cyst; however, they could not identify the solid areas of the cyst described by Dr. Granville and concluded that the cyst must have been benign and, therefore, not lethal (Granville, 1825: 300; Harer et al., 2014: 104-106). Following the dismissal of the original cause of death, the question remained as

Reconstructing Irtysenu

to what the cause of death could have been. Due to new knowledge and developments in paleopathology, it is now possible to test for tropical diseases known to have affected the ancient Egyptian people, and thus, malaria was raised as a possible cause of death.

The Malaria Diagnosis

Malaria is caused by a single-celled parasite in the genus *Plasmodium* and is transmitted through the bites of infected mosquitoes (Nerlich, 2016: 1-2). In 1994, Irtysenu was one of 16 mummies examined for malaria using immunological methods, specifically the modified ParaSightTM-F test, and was among seven mummies that tested positive, by testing a muscle sample (Miller et al., 1994; Nerlich, 2016). However, this specific immunological test showed many false positives, prompting a re-examination in 1997 using ancient DNA analysis (Donoghue et al., 2010: 52).

Here, three individuals were used as the basis for the study: two males who died in the 1930s with malaria as their cause of death, and Irtysenu, whereof only one modern sample tested positive for malaria (Taylor et al., 1997: 194). All three individuals also underwent the ParaSightTM-F test, the same immunological test used in 1994, and all three samples tested negative for malaria.

In both malaria testing, skeletal muscle was used as the sample, and appropriate methods were used to avoid cross-contamination (Miller et al., 1994: 31; Taylor et al., 1997: 194). However, soft tissues, such as skeletal muscle, are often heavily contaminated by environmental factors, and that is likely the case here (Orlando et al., 2021: 2). Both the mummification process could have affected the soft tissue, and as there is no evidence of Dr. Granville using gloves, masks, or other ways of avoiding contamination, this could have resulted in Dr. Granville, or any of his guests, contaminating the soft tissue as well, especially since Dr. Granville himself was infected with malaria (Granville, 1825; Orlando et al., 2021: 2; Pain, 2008, p. 72). Another contamination factor is the arm from a 'North African' mummy and parts of four human fetuses that the remains of Irtysenu were stored with following the autopsy (British Museum, 2026b).

Furthermore, although it is possible to extract viable ancient DNA from ancient Egyptian mummies, it is often highly degraded, and earlier researchers suggest that the upper limit for good DNA preservation in Egypt is around 800-700 BCE, but whole genomes have been sequenced from the Early Old Kingdom from around 2855-2570 BCE (Marota et al., 2002: 316-318; Morez Jacobs et al., 2025).

The Tuberculosis Diagnosis

Tuberculosis is an airborne disease caused by the genus *Mycobacterium* and is transmitted through air droplets from an infected individual (Donoghue et al., 2010: 51). Here, samples from both soft and hard tissue were used to test her for tuberculosis. The tuberculosis complex was detected in lung, gallbladder, and other

soft-tissue samples, confirming the diagnosis (Donoghue et al., 2010: 52-53).

The greatest quantity of *Mycobacterium tuberculosis* complex was found in the lung tissue, which led Donoghue et al. (2010) to argue that Lady Irtysenu had pulmonary tuberculosis, that had spread to other parts of the body, as there was also tuberculosis found in the gallbladder and other soft tissue samples (Donoghue et al., 2010: 55). If available, the ribs and vertebrae could have been examined for lesions developed from heavy coughing associated with the disease, however, these were discarded after the original autopsy in 1821 (Roberts et al., 1998). A second autopsy, which was conducted in 1994, supports the diagnosis of pulmonary tuberculosis (Donoghue et al. 2010: 55). This second autopsy noted that the skeletal muscles instead indicated wasting and not obesity, which would be consistent with an active tuberculosis infection (Donoghue et al., 2010: 55).

The Possible Weight Loss

Several factors can contribute to the possible obesity or weight loss described by Dr. Granville (1825) in his original autopsy report, where he stated, "Numerous and deep wrinkles appeared on the integuments of the abdomen, denoting that before death, this part of the body must have had very considerable dimensions" (Granville, 1825: 277). Although the number of wrinkles visible may have resulted from the dehydration of the mummification process, it may also have occurred during Irtysenu's lifetime. This statement could be supported by the symptoms of pulmonary tuberculosis recorded in the present day, including loss of appetite and unexplained weight loss. However, it can take months or years for the symptoms to develop (Dryer 2010, pp. 1-28). The ovarian cyst could also have affected weight loss, depending on what kind of cyst it was (Dryer, 2010: 6). If an ovarian cyst becomes large enough to press on the abdomen, symptoms such as nausea and vomiting can develop, which, in theory, could have affected the life of Irtysenu, making it challenging to keep food down and, therefore, lose weight.

However, an ovarian cyst can also produce rapid weight gain (Neighbors et al., 2010: 367-368). A third scenario could be that the weight loss was a side effect of both the ovarian cyst and the tuberculosis infection overwhelming her body. Both benign and malignant ovarian cysts can weaken the immune system, both directly and indirectly through hormonal imbalance, inflammation, stress, among others, making her more susceptible to contracting other diseases (Neighbors et al. 2010: 367-368). This is also an excellent example of comorbidities in an Egyptian individual, with two diseases present: an ovarian cyst and tuberculosis.

If Irtysenu had been discovered today, it would have been possible to conduct a CT scan of the ovarian cyst identified by Dr. Granville (1825) to assess its size and characteristics, which would have aided research into the pathology of the cyst. This could also have supported the hypothesis of the cyst's benign status (Harer et al., 2014: 106). The ovarian cyst could have made her more receptive to other diseases, such as malaria and/or tuberculosis, especially if the cyst had been symptomatic. Furthermore, it would have been possible to perform a chest X-ray to look for lesions

or tubercles in the lungs in relation to a tuberculosis infection. Dr. Granville examined the lungs in 1821, but there are no notes regarding lesions or tubercles being present, and neither has there been a more recent examination of the lungs (Granville, 1825: 296).

Ethical Consideration

Despite the advancement of methods, the dehumanization of ancient remains is still an issue, as seen with 'Granville's Mummy', arguably stripping the personhood or rights of the deceased individuals, as ancient remains are not able to provide consent to the use of their remains (Fox & Hawks, 2019; Robbins Schug et al., 2025). Today, ancient remains are often stored in boxes in storage rooms, laboratories or museums (Robbins Schug et al., 2025: 2), used for teaching in schools or exhibitions at museums (Robbins Schug et al., 2025: 6-7), among others, often removed from other archaeological material found with the individual, supporting the issue of dehumanization of ancient remains (Fox & Hawks, 2019: 581-583; Robbins Schug et al., 2025: 1-16). Especially for ancient Egyptian individuals, various items were provided to ensure safe passage to and comfortable living in the afterlife (Meskell, 1999: 184-185). The latter being a greater issue with the antiquity dealers of the 18th and 19th centuries, who would also switch around the mummies and their coffins, resulting in the loss of identity of the individuals (Vandenbeusch et al., 2021).

In the case of Irtysenu and Dr. Granville, no mention of ethics or the consideration thereof was present, although there is evidence of careful consideration regarding how to conduct the autopsy and the documentation thereof (Granville, 1825, 1833). Here, it appears that he viewed her mummified remains as a beautiful and curious specimen rather than as a deceased human being, despite their remarkably well-preserved state (Granville, 1825: 301). A similar example was brought up by Fox and Hawks (2019). Here, multiple crania were sampled for DNA from the petrous bone, which is the dense bone that contains the inner ear and also has high concentrations of biomarkers. The sampling was done by drilling into the bone, essentially destroying it, without first taking photographs or using other documenting tools, such as CT scans or X-rays, to ensure morphological records of the bone, essentially destroying the personhood of the individuals (Fox & Hawks, 2019: 582).

Although modern researchers have become more ethical in their treatment of ancient remains, there are still ways to improve their handling, such as keeping individuals with their archaeological finds, reburial when possible, and ensuring proper documentation of the individuals and their findings.

Conclusions

As this article highlights, re-examining ancient remains can provide new insights into the people of the past. Many changes have occurred over the last 200 years in how ancient remains are examined, and although ancient Egyptian mummies remain of great interest, they are no longer publicly unwrapped for entertainment. The ethics surrounding the handling of ancient remains have improved greatly, but there is still room for improvement.

Despite the original autopsy report done by Dr. Granville (1825), it does show great consideration in terms of documentation, which has aided greatly, as the once perfectly preserved ancient individual was destroyed during the autopsy process. However, Dr. Graville's original findings, such as his estimation of race, possible obesity, and cause of death, have changed through time since newer examination technologies have been developed. This article provides a reconstruction of a single individual's journey through the medical field, attempting to illustrate how methods and technologies can change the outcomes of, for instance, racial theories and cause-of-death assessments, as well as the ethical concerns of examinations.

However, there is much to learn from ancient individuals, and great consideration should be given before using destructive methods. Nonetheless, discoveries are still possible with less and less material, and there may still be more to learn about Irtysenu, Lady of the House.

Bibliography

- AlQahtani, S. J. et al. (2010). Brief communication: The London atlas of human tooth development and eruption. *American journal of physical anthropology*, 142(3), 481–490. <https://doi.org/10.1002/ajpa.21258>
- Brier, B. (2004). Infectious diseases in ancient Egypt. *Infectious Disease Clinics of North America*. [Online] 18 (1), 17–27. [https://doi-org.ep.fjernadgang.kb.dk/10.1016/S0891-5520\(03\)00097-7](https://doi-org.ep.fjernadgang.kb.dk/10.1016/S0891-5520(03)00097-7)
- British Museum (2026a). Coffin, Museum Number: EA29781. The British Museum. Retrieved March 5, 2026, from https://www.britishmuseum.org/collection/object/Y_EA29781?selectedImageId=364427001
- British Museum (2026b). Human Remains, Museum Number: EA75991. The British Museum. Retrieved February 7, 2026, from https://www.britishmuseum.org/collection/object/Y_EA75991.
- Buckberry, J. L. & Chamberlain, A. T. (2002). Age estimation from the auricular surface of the ilium: a revised method. *American Journal of Physical Anthropology: The Official Publication of the American Association of Physical Anthropologists*, 119(3), 231-239. <https://onlinelibrary.wiley.com/doi/pdf/10.1002/ajpa.10130>
- Cianferotti, L. & Brandi, M. L. (2013). "Pathogenesis of osteoporosis" in Reginster, J., & Bruyère, O. (Eds.). *Osteoporosis*. Future Medicine Ltd.
- Clinker, S. (2024). Unraveling Mummy Objectification: An Evaluation of the History and Legacy of Mummymania. *The International Journal of the Inclusive Museum*, 17(1), 107–126. <https://doi.org/10.18848/1835-2014/CGP/v17i01/107-126>
- Cornelius, S. (2010). Ancient Egypt and the other. *Scriptura: Journal for Contextual Hermeneutics in Southern Africa*, 104(1), 322-340.
- David, A. (2008a). The International Ancient Egyptian Mummy Tissue Bank. In R. David (Ed.), *Egyptian Mummies and Modern Science* (pp. 237-246). Cambridge: Cambridge University Press. Doi:10.1017/CBO9780511499654.016
- David, R. (2008b). "Egyptian mummies: an overview", in David, R. (Ed.) *Egyptian Mummies and Modern Science*. Cambridge University Press. pp. 10-18. Doi:10.1017/CBO9780511499654.016
- Dawson, W. R. (1925). A Mummy of the Persian Period. *Journal of Egyptian archaeology*. [Online] 11 (1/2), 76–77. <https://www.jstor.org/stable/3854276>

Reconstructing Irtysenu

Dieleman, J. & Moyer, I. S. (2010). "Egyptian Literature". In Clauss, James J.; Cuypers, Martine (Eds.). *A Companion to Hellenistic Literature*. John Wiley & Sons. p. 429-447. DOI:10.1002/9781118970577

Donoghue, H. D. et al. (2010). Tuberculosis in Dr Granville's Mummy: A Molecular Re-Examination of the Earliest Known Egyptian Mummy to Be Scientifically Examined and Given a Medical Diagnosis. *Proceedings: Biological Sciences*, 277(1678), 51–56. <http://www.jstor.org/stable/40506087>

Fox, K. & Hawks, J. (2019). Use ancient remains more wisely. *Nature (London)*. [Online] 572 (7771), 581–583. doi: <https://doi.org/10.1038/d41586-019-02516-5>

Granville, A. B. (1825). *An Essay on Egyptian Mummies; With Observations on the Art of Embalming among the Ancient Egyptians*. *Philosophical transactions of the Royal Society of London*. [Online] 115 (2), 269–316. DOI: <https://doi.org/10.1098/rstl.1825.0015>

Granville, A. B. (1833). *An essay on Egyptian mummies ; with observations on the art of embalming among the ancient Egyptians*. *Abstracts of the papers printed in the Philosophical transactions of the Royal Society of London*. [Online] 2240–241. <https://royalsocietypublishing.org/doi/pdf/10.1098/rspl.1815.0260>

Grauer, Anne. (2018). A century of paleopathology. *American journal of physical anthropology*. 165. 904-914. <https://doi-org.ep.fjernadgang.kb.dk/10.1002/ajpa.23366>

Harer, W. B. & Tapp, E. (2014). Augustus Bozzi Granville (1783–1872): Pioneer obstetrician and gynaecological surgeon who performed the first scientific autopsy of a mummy. *Journal of medical biography*. [Online] 22 (2), 101–107. DOI: 10.1177/0967772013480607

Hedges, R. E. M. et al. (1997). Radiocarbon Dates from the Oxford Ams System: *Archaeometry Datelist 23*. *Archaeometry*. [Online] 39 (1), 247–262. <https://doi-org.ep.fjernadgang.kb.dk/10.1111/j.1475-4754.1997.tb00803.x>

Herodotus. (II). *The History of Herodotus — Volume 1*. Project Gutenberg. https://www.gutenberg.org/cache/epub/2707/pg2707-images.html#link22H_4_0001

Ikram, S. & Dodson, A. (1998). *The mummy in ancient Egypt: equipping the dead for eternity*. Thames and Hudson.

Ikram, S. (2020). Mummies and physical anthropology. In *The Oxford Handbook of Egyptology*. Oxford University Press. <https://doi.org/10.1093/oxfordhb/9780199271870.013.20>

Lambert, P.M. & Walker (Deceased), P.L. (2018). Bioarchaeological Ethics. In *Biological Anthropology of the Human Skeleton* (eds M.A. Katzenberg and A.L. Grauer). <https://doi-org.ep.fjernadgang.kb.dk/10.1002/9781119151647.ch1>

Lovejoy, C. O. et al. (1985). Chronological metamorphosis of the auricular surface of the ilium: a new method for the determination of adult skeletal age at death. *American journal of physical anthropology*, 68(1), 15-28.

Marota, I. et al. (2002). DNA decay rate in papyri and human remains from Egyptian archaeological sites. *American Journal of Physical Anthropology*, 117(4), 310–318. <https://doi.org/10.1002/ajpa.10045>

Meskel, L. (1999). Archaeologies of Life and Death. *American Journal of Archaeology*, 103(2), 181–199. <https://doi.org/10.2307/506744>

Miller, R.L. (1994). Diagnosis of *Plasmodium falciparum* infections in mummies using the rapid manual ParaSight TM-F test. *Trans. R. Soc. Trop. Med. Hyg.* 88, 31–32. [https://doi-org.ep.fjernadgang.kb.dk/10.1016/0035-9203\(94\)90484-7](https://doi-org.ep.fjernadgang.kb.dk/10.1016/0035-9203(94)90484-7)

Morez Jacobs, A. et al. (2025). Whole-genome ancestry of an Old Kingdom Egyptian. *Nature*, 644(8077), 714-721.

Murray, M. (1910). *The tomb of the two brothers*. Sherratt & Hughes. London.

Neighbors, M. & Tannehill-Jones, R. (2010). *Human diseases*. 3. ed., international ed. Clifton Park, NY: Delmar, Cengage Learning. Pp. 95-124; pp. 175-201; pp. 357-393.

Nerlich, A. (2016). Paleopathology and Paleomicrobiology of Malaria. *Microbiology spectrum*. [Online] 4 (6). <https://doi-org.ep.fjernadgang.kb.dk/10.1128/microbiolspec.poh-0006-2015>

Nunn, J. & Tapp, E. (2000). Tropical diseases in Ancient Egypt. *Transactions of the Royal Society of Tropical Medicine and Hygiene*. [Online] 94 (2), 147–153. [https://doi-org.ep.fjernadgang.kb.dk/10.1016/S0035-9203\(00\)90252-9](https://doi-org.ep.fjernadgang.kb.dk/10.1016/S0035-9203(00)90252-9)

Orlando, L. et al. (2021). Ancient DNA analysis. *Nature reviews methods primers*, 1(1), 14.

Pain, S. (2008). What killed Dr Granville's mummy. *New Scientist*. 2008; 199(2687):72-73. Accessed May 4, 2022. DOI: 10.1016/s0262-4079(08)63245-5

Pettigrew, T.J. (1837). 'Account of the Examination of the Mummy of Pet-Maut-Ioh-Mes brought from Egypt by the late John Gosset Esq.', *Archaeologia* 27: 262-73.

Riggs. (2016). An Autopsic Art: Drawings of “Dr Granville’s Mummy” in the Royal Society Archives. *Notes and Records of the Royal Society of London*, 70(2), 107–133. <https://doi.org/10.1098/rsnr.2015.0050>

Roberts, C. A. et al. (1998). Rib lesions and tuberculosis: the palaeopathological evidence. *Tubercle and Lung Disease*, 79(1), 55–60. <https://doi.org/10.1054/tuld.1998.0005>.

Robbins Schug, G. et al. (2025). They Are People Too: The Ethics of Curation and Use of Human Skeletal Remains for Teaching and Research. *Am J Biol Anthropol*, 186: e70013. <https://doi.org/10.1002/ajpa.70013>

Taylor, G.M., Rutland, P., & Molleson, T. (1997). A sensitive polymerase chain reaction method for the detection of Plasmodium species DNA in ancient human remains. *Ancient Biomolecules*. 1, 193–204.

Vandenbeusch, M., Stacey, R., & Antoine, D. (2021). Rediscovering Nestawedjat: Embalming residue analyses reunite the mummified remains of an ancient Egyptian woman with her coffins. *Journal of Archaeological Science: Reports*, 40, 103186. <https://doi.org/10.1016/j.jasrep.2021.103186>

Villa, C., Davey, J., Craig, P. J., Drummer, O. H., & Lynnerup, N. (2015). The advantage of CT scans and 3D visualizations in the analysis of three child mummies from the Graeco-Roman Period. *Anthropologischer Anzeiger*, 72(1).